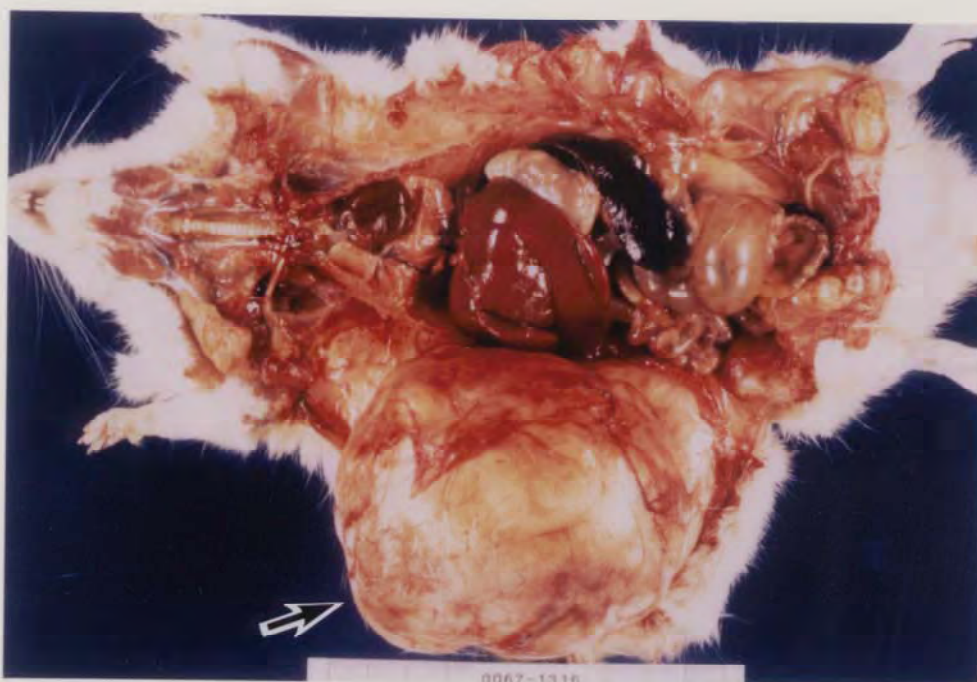


1,2-ジクロロエタンのラット及びマウスを用いた
吸入によるがん原性試験報告書

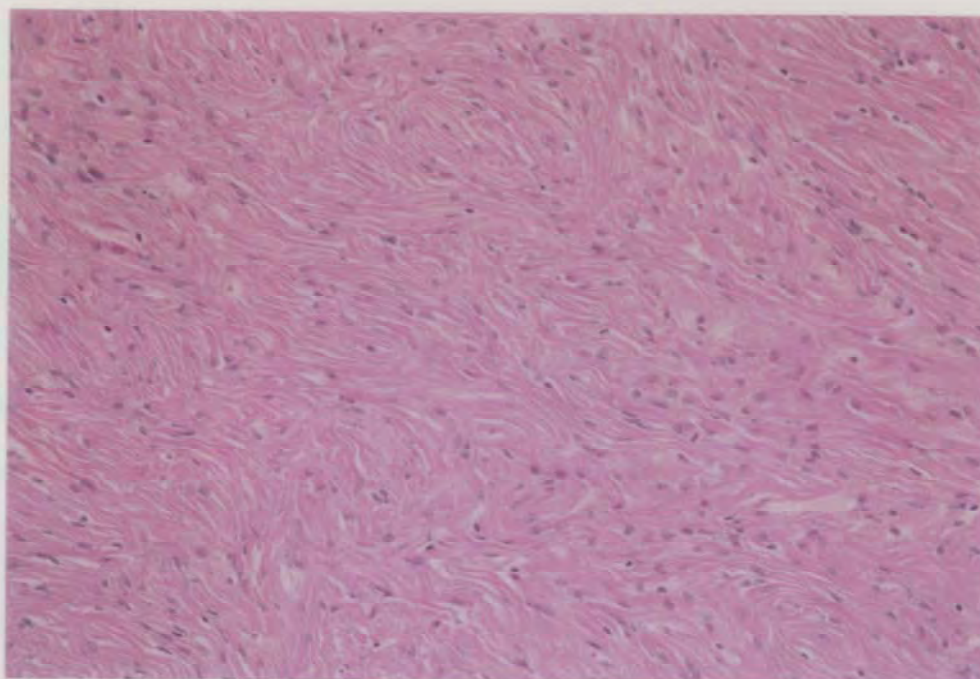
試験番号

急性性 : ラット/0041 ; マウス/0042
2週間 : ラット/0047 ; マウス/0048
13週間 : ラット/0055 ; マウス/0056
がん原性 : ラット/0067 ; マウス/0068

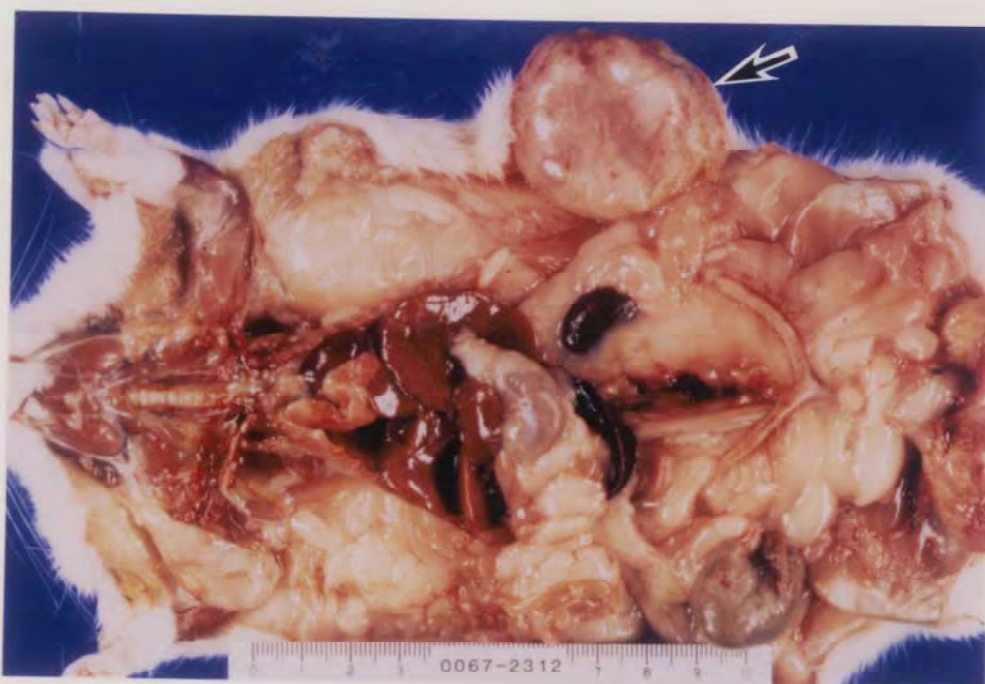PHOTOGRAPHS



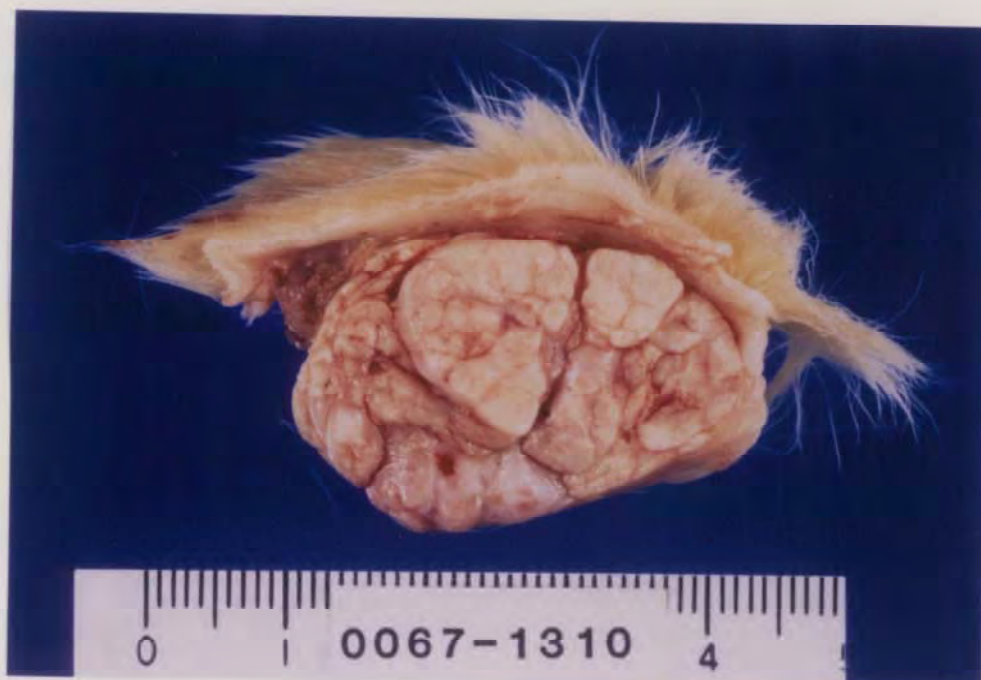PHOTOGRAPH 1 SUBCUTIS, MASS (→) (SUBCUTIS, FIBROMA)
 RAT, MALE, 160ppm, ANIMAL NO. 0067-1316



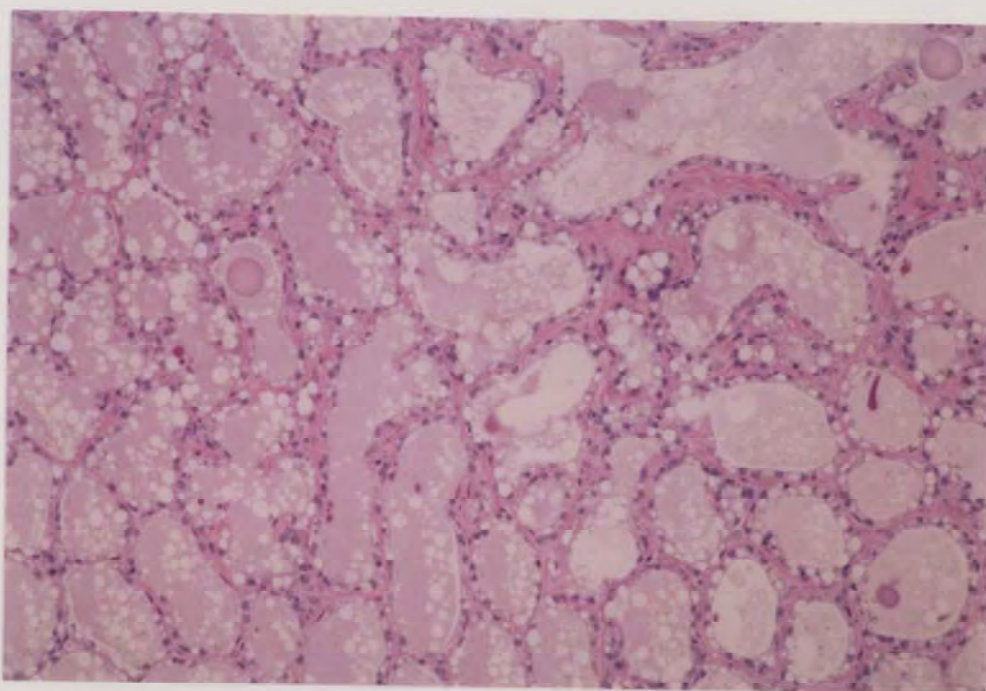
PHOTOGRAPH 2 SUBCUTIS, FIBROMA
 RAT, MALE, 160ppm, ANIMAL NO. 0067-1338



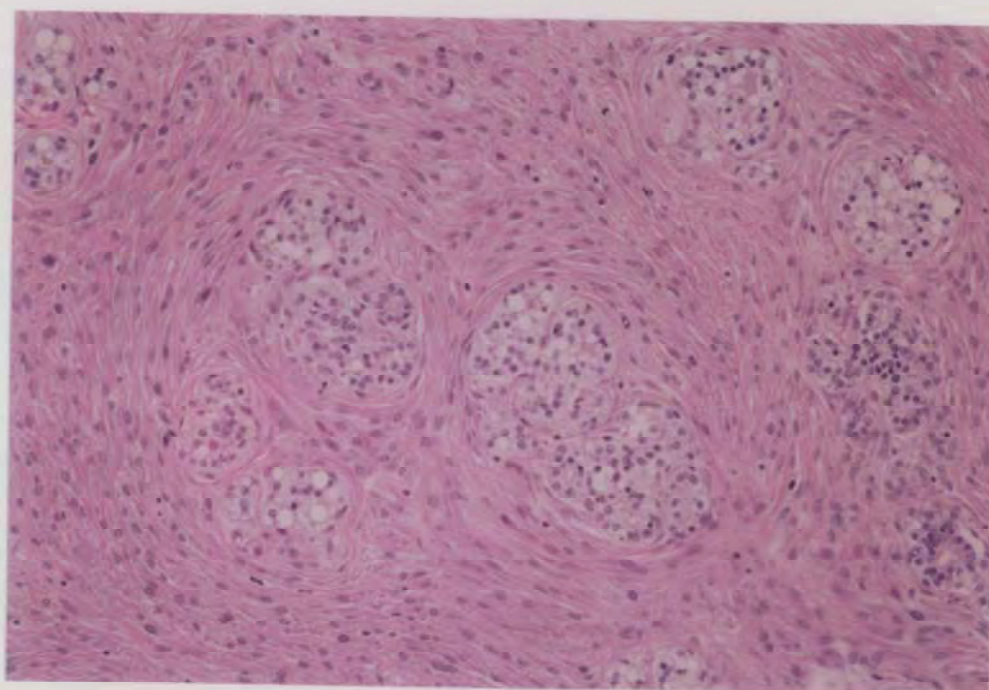
PHOTOGRAPH 3 SUBCUTIS, MASS (→) (MAMMARY GLAND, ADENOMA)
RAT, FEMALE, 160ppm, ANIMAL NO. 0067-2312



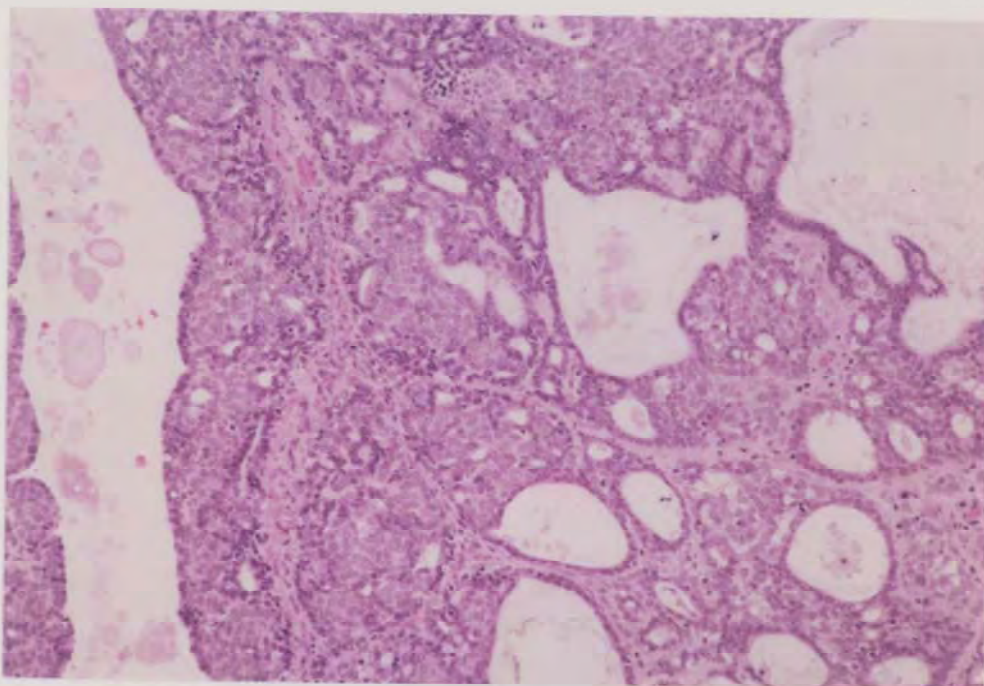
PHOTOGRAPH 4 SUBCUTIS, MASS, CROSS SECTION (MAMMARY GLAND, FIBROADENOMA)
RAT, MALE, 160ppm, ANIMAL NO. 0067-1310



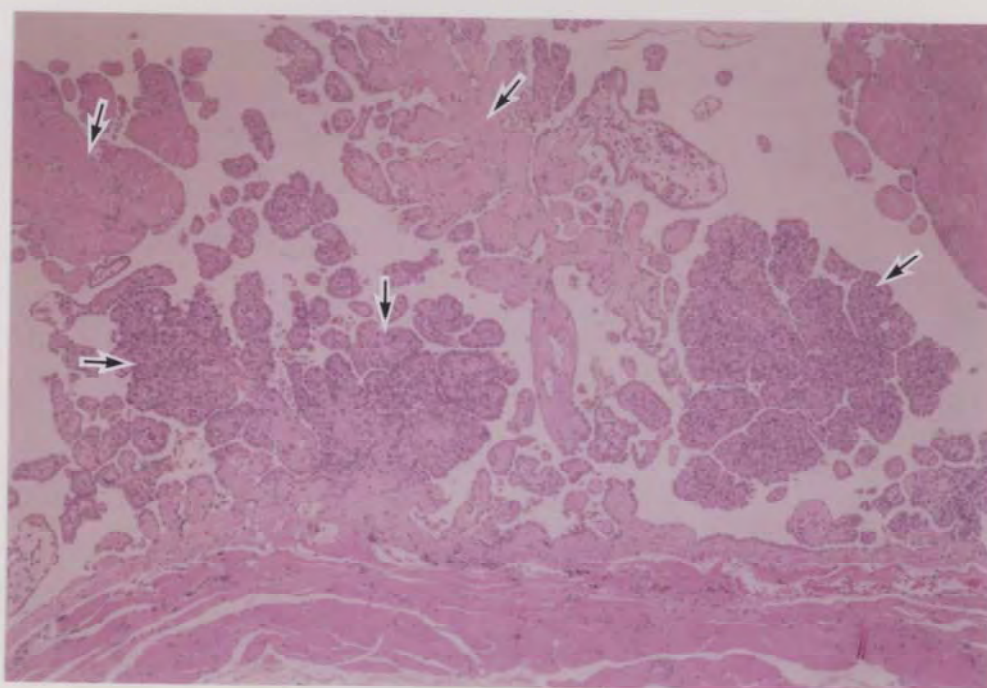
PHOTOGRAPH 5 MAMMARY GLAND, ADENOMA
RAT, FEMALE, 160ppm, ANIMAL NO.0067-2341 (H. E. , X150)



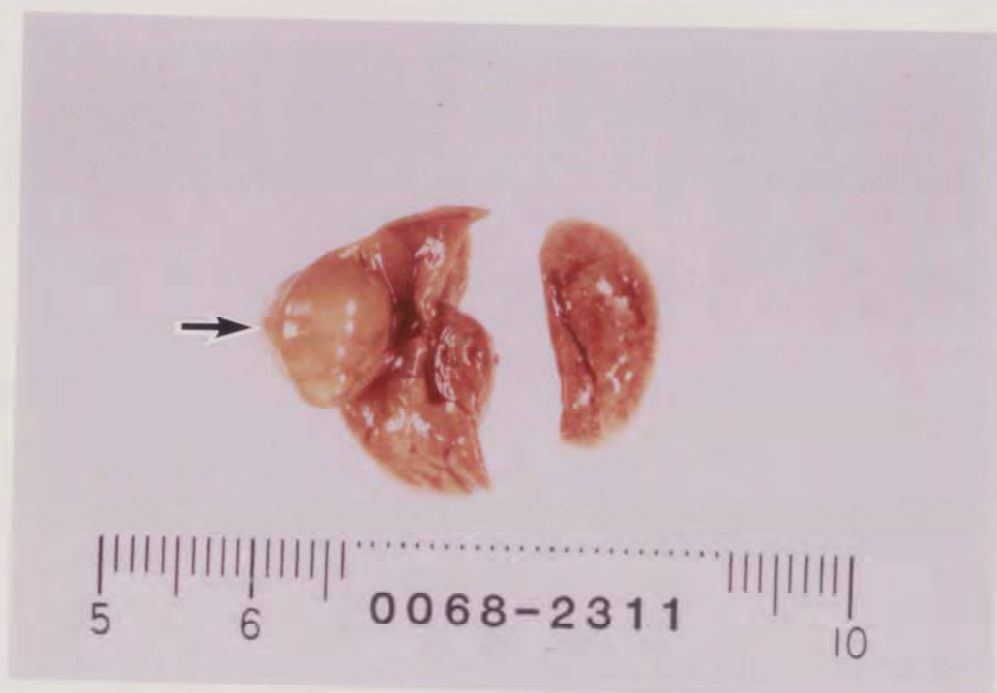PHOTOGRAPH 6 MAMMARY GLAND, FIBROADENOMA
RAT, FEMALE. 160ppm, ANIMAL NO.0067-2302 (H. E. , X150)



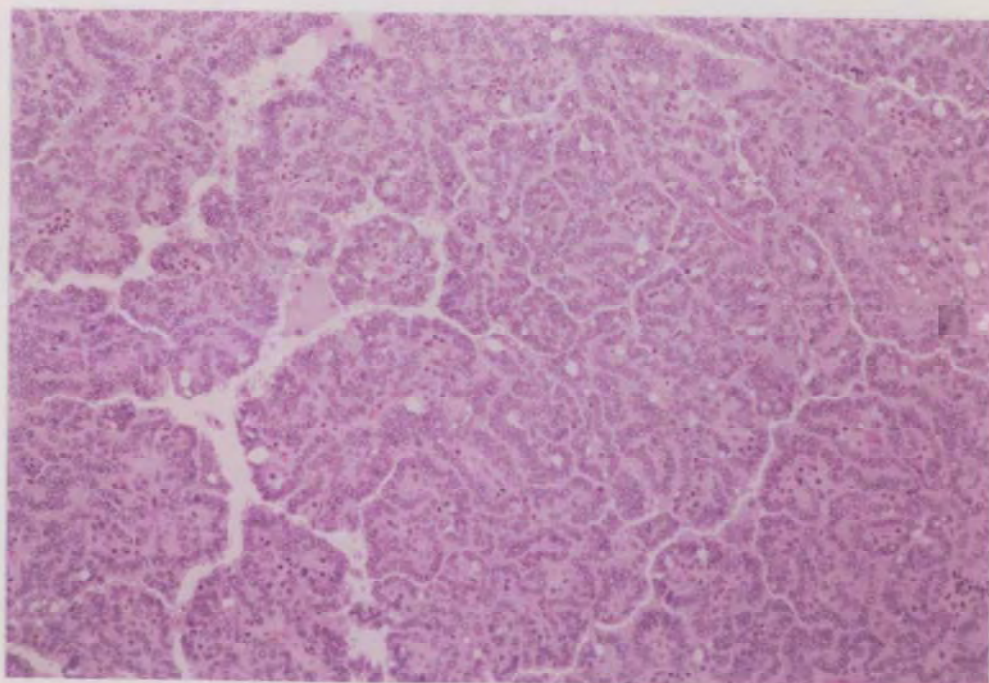
PHOTOGRAPH 7 MAMMARY GLAND, ADENOCARCINOMA
RAT, FEMALE, 160ppm, ANIMAL NO.0067-2307 (H. E. , X150)



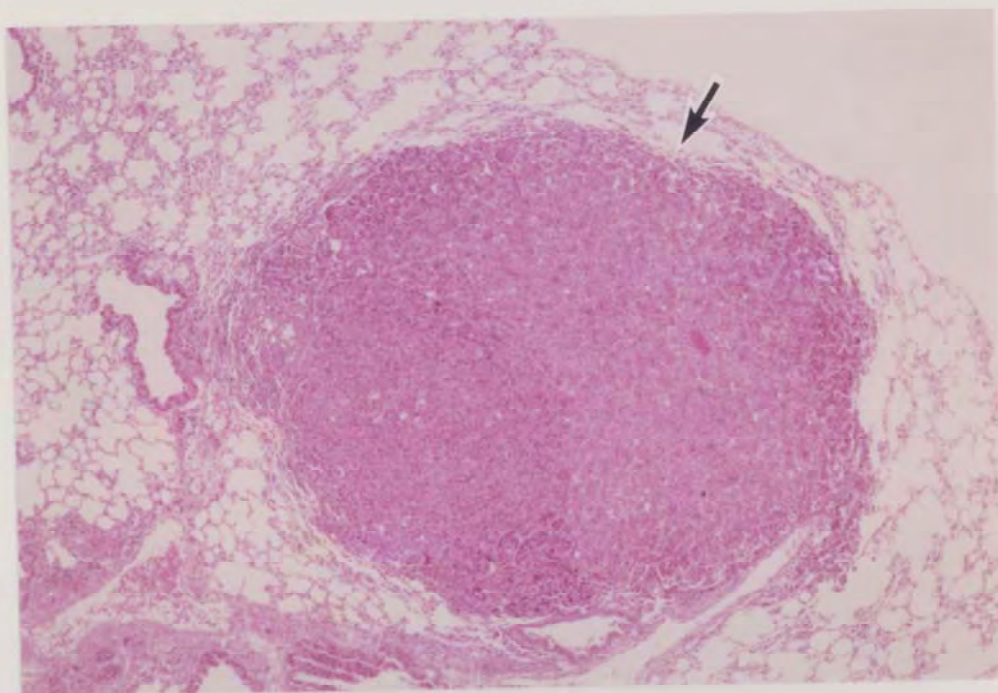
PHOTOGRAPH 8 PERITONEUM, MESOTHELIOMA (→)
RAT, MALE, 160ppm, ANIMAL NO.0067-1342 (H. E. , X60)



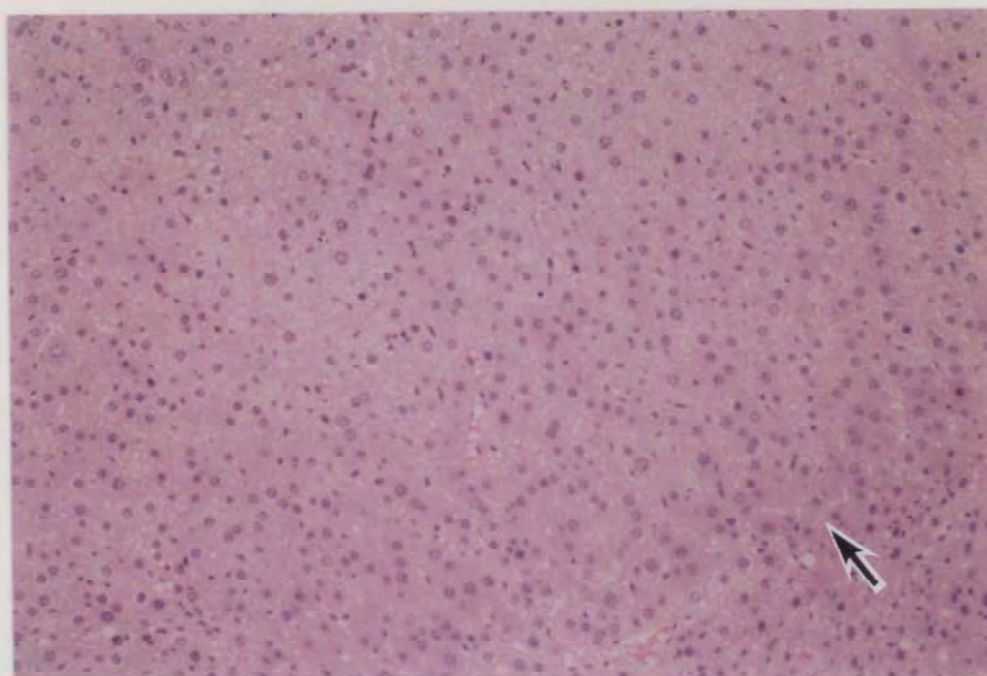
PHOTOGRAPH 9 LUNG, NODULE (→) (BRONCHIOLAR-ALVEOLAR CARCINOMA)
 MOUSE, FEMALE, 90ppm, ANIMAL NO. 0068-2311



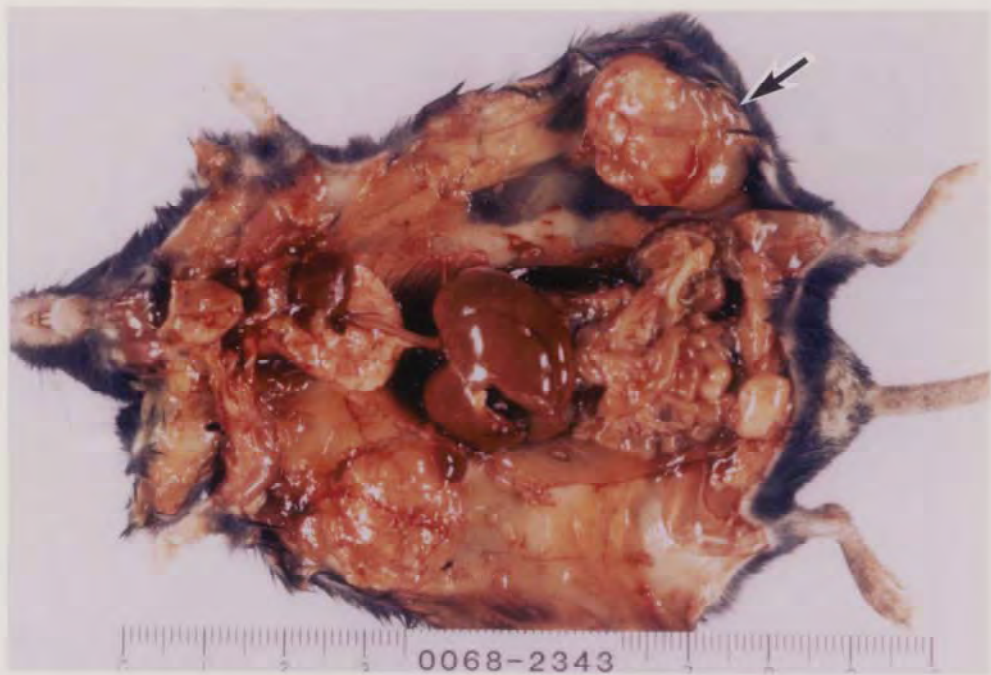PHOTOGRAPH 10 LUNG, BRONCHIOLAR-ALVEOLAR CARCINOMA
 MOUSE, FEMALE, 90ppm, ANIMAL NO. 0068-2311 (H. E., X150)



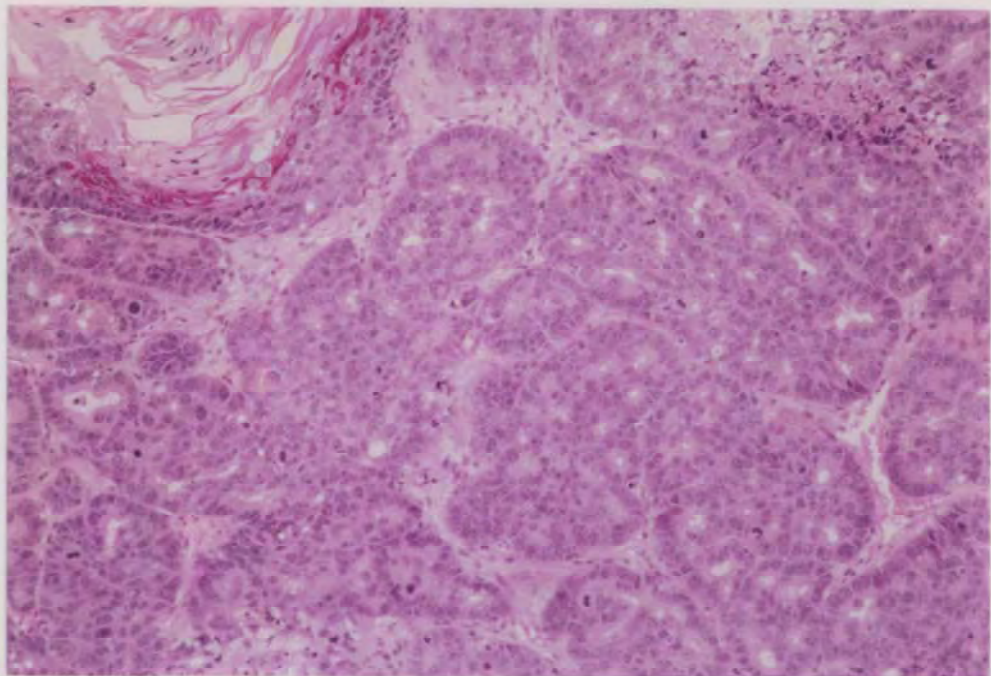
PHOTOGRAPH 11 LUNG, BRONCHIOLAR-ALVEOLAR ADENOMA (→)
MOUSE, FEMALE, 90ppm, ANIMAL NO.0068-2350 (H.E., X60)



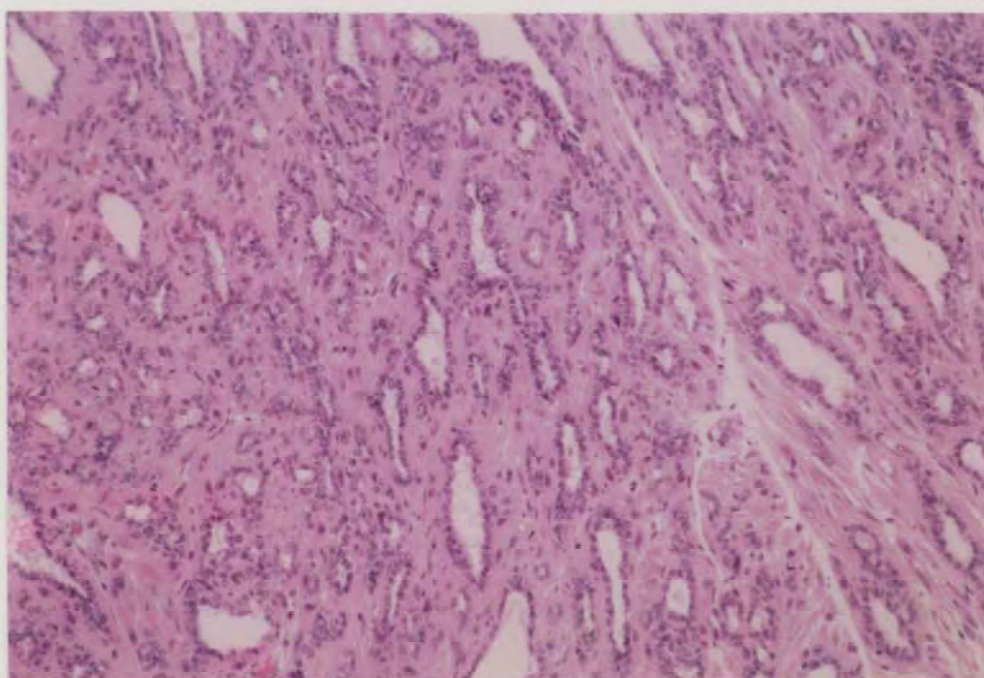
PHOTOGRAPH 12 LIVER, HEPATOCELLULAR ADENOMA (→)
MOUSE, FEMALE, 90ppm, ANIMAL NO.0068-2315 (H.E., X150)



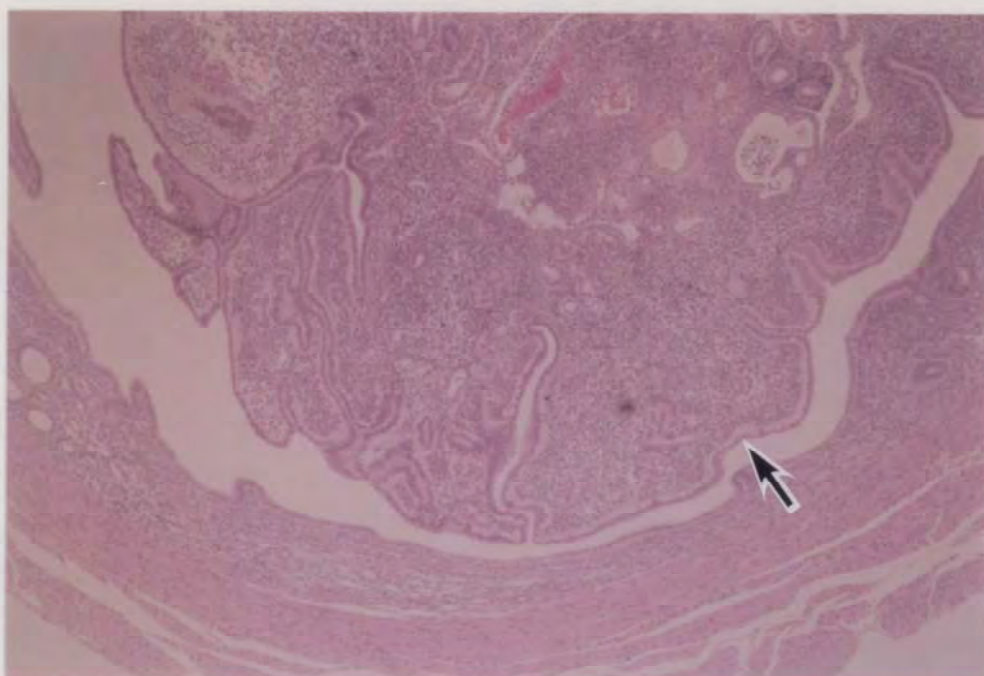
PHOTOGRAPH 13 SUBCUTIS, MASS (→) (MAMMARY GLAND, ADENOCARCINOMA)
MOUSE, FEMALE, 90ppm, ANIMAL NO. 0068-2343



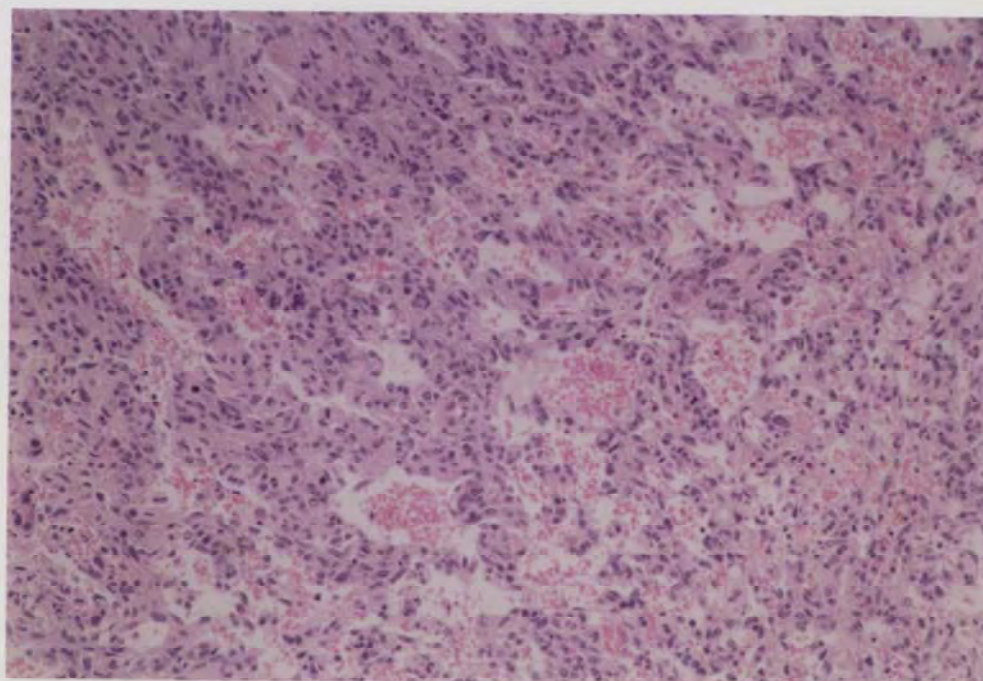
PHOTOGRAPH 14 MAMMARY GLAND,
ADENOCARCINOMA, TYPE-B WITH SQUAMOUS CELL METAPLASIA
MOUSE, FEMALE, 90ppm, ANIMAL NO. 0068-2343 (H. E., X150)



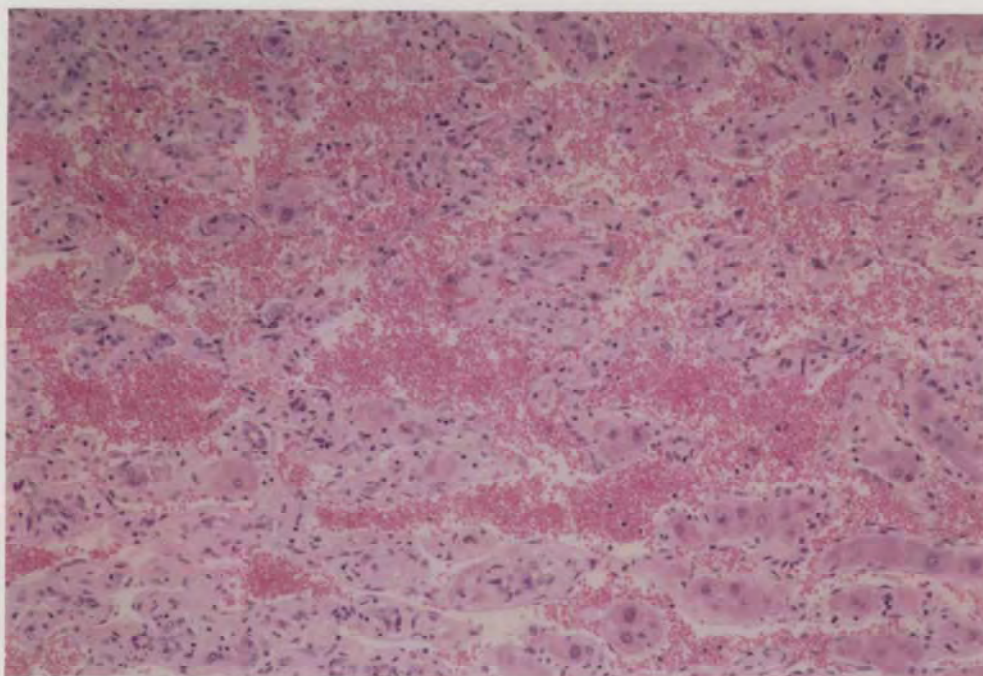
PHOTOGRAPH 15 MAMMARY GLAND, ADENOCARCINOMA, TYPE-C
MOUSE, FEMALE, 90ppm, ANIMAL NO. 0068-2327 (H. E., X150)



PHOTOGRAPH 16 UTERUS, ENDOMETRIAL STROMAL POLYP (→)
MOUSE, FEMALE, 90ppm, ANIMAL NO. 0068-2343 (H. E., X60)



PHOTOGRAPH 17 LIVER, HEMANGIOSARCOMA
 MOUSE, MALE, 30ppm, ANIMAL NO. 0068-1210 (H. E., X150)



PHOTOGRAPH 18 LIVER, HEMANGIOSARCOMA
 MOUSE, MALE, 90ppm, ANIMAL NO. 0068-1317 (H. E., X150)